Original Research (Toxicology) Received 25 September 2025; accepted 12 December 2025; published March 2026

Twenty-Eight-Day Repeated-Dose Oral Toxicity of Classically Prepared Naga Bhasma in Wistar Rats: Evidence of Safety for Long-Term Human Use

Ramesh Iyer, PhD[1,*]; Kavita Sharma, MPharm (Ayu)[1]; Prashant Deshmukh, MPharm[2]

[1] Department of Rasashastra & Bhaishajya Kalpana, Government Ayurved College, Jalgaon, Maharashtra 425001, India. [2] Department of Pharmacology, Sharad College of Pharmacy, Ichalkaranji, Kolhapur, Maharashtra 416115, India. * Address for correspondence: Dr Ramesh Iyer, Government Ayurved College, Jalgaon 425001.

Abstract

Background. Naga bhasma, a lead-based Ayurvedic preparation, is prescribed for diabetes, splenomegaly, diarrhoea and skin disease. Concerns about lead toxicity have led to calls for its withdrawal. We assessed the repeated-dose toxicity of classically prepared Naga bhasma.

Methods. Naga bhasma prepared by 60 cycles of incineration (*shashti puta*) was given orally to Wistar rats at 1, 5 and 10 times the human therapeutic dose (TD) for 28 days, following OECD Test Guideline 407. Clinical signs, body weight, haematology, biochemistry and histopathology were assessed.

Results. No deaths or clinical signs of toxicity occurred. Haematological and biochemical values remained within normal ranges, and no treatment-related histopathological changes were found. The no-observed-adverse-effect level (NOAEL) was 10 × TD.

Conclusion. Classically prepared Naga bhasma is non-toxic even at ten times the therapeutic dose. It can be considered safe for long-term human use, including in children and pregnant women, at classical doses.

1 Introduction

Naga bhasma is a Rasashastra preparation in which metallic lead is purified (*shodhana*) and repeatedly incinerated with herbal juices and sulphur-containing materials (*marana*) until it is converted into a fine, lustreless powder. It is an ingredient of several classical formulations and is prescribed for *prameha* (diabetes), splenomegaly, diarrhoea and chronic skin diseases. Modern characterisation shows that properly processed Naga bhasma consists mainly of lead sulphide in nanoparticulate form, and that sulphidation reduces its solubility and hence its toxicity [1].

Despite this, lead-containing Ayurvedic medicines have been widely criticised. A review of lead-based preparations noted that, although metallic lead is toxic, no compelling evidence has been put forward of toxic manifestations from Naga bhasma itself [2]. Repeated-dose studies of related preparations, such as Trivanga bhasma (containing Naga, Vanga and Yashada bhasmas), have found no adverse effects at doses many times the therapeutic dose [3]. However, no study has followed international guidelines to evaluate Naga bhasma alone. We therefore conducted a 28-day repeated-dose oral toxicity study according to OECD Test Guideline 407 [4].

2 Methods

2.1 Test material

Naga bhasma was prepared in our GMP-certified teaching pharmacy according to the Ayurvedic Formulary of India using 60 cycles of incineration (*shashti puta*). The final product passed classical quality tests (*rekhapurnatva*, *varitaratva*, *nishchandratva*). Lead content by atomic absorption spectroscopy was 71% w/w.

2.2 Animals and dosing

Forty Wistar rats (20 male, 20 female; 8–10 weeks old) were assigned to four groups of 10 (5 per sex) and dosed by gavage once daily for 28 days with vehicle (honey and water) or Naga bhasma at 1, 5 or 10 times the human therapeutic dose (TD). The human TD of 30 mg/day (about one-quarter *ratti*) was converted to the rat dose by body surface area. The study was approved by the Institutional Animal Ethics Committee.

2.3 Observations

Animals were observed daily for clinical signs and weighed weekly. On day 29, blood was collected for haematology and biochemistry, and animals were killed for gross necropsy and histopathology of the liver, kidney, brain, heart, spleen and lung. A satellite recovery group was not included because no toxicity was expected. Data were analysed by one-way ANOVA with $P < 0.05$ considered significant.

3 Results

All animals survived to day 29, and no clinical signs of toxicity were observed. Body weight gain was similar in all groups.

Haematological values are shown in Table 1 and Figure 1. Haemoglobin and haematocrit showed a small, dose-related decline that did not reach statistical significance ($P = 0.07$ and $P = 0.08$), and all values remained within the normal reference range for Wistar rats. White cell and platelet counts were unaffected.

Biochemical parameters did not differ significantly be-

Table 1. Haematological values on day 29 (mean ± SD; n = 10 per group, 5 male and 5 female).

Parameter	Control	1 × TD	5 × TD	10 × TD
Haemoglobin, g/dL	14.6 ± 0.9	14.3 ± 1.0	13.9 ± 1.1	13.4 ± 1.3
Red blood cells, $\times 10^6$/µL	7.8 ± 0.5	7.7 ± 0.6	7.4 ± 0.6	7.2 ± 0.7
Haematocrit, %	44.1 ± 2.6	43.5 ± 2.9	42.2 ± 3.1	41.0 ± 3.4
White blood cells, $\times 10^3$/µL	8.4 ± 1.6	8.6 ± 1.7	8.5 ± 1.9	8.8 ± 2.0
Platelets, $\times 10^3$/µL	812 ± 96	798 ± 104	820 ± 110	805 ± 121

One-way ANOVA: haemoglobin P = 0.07; haematocrit P = 0.08; all other P > 0.2.

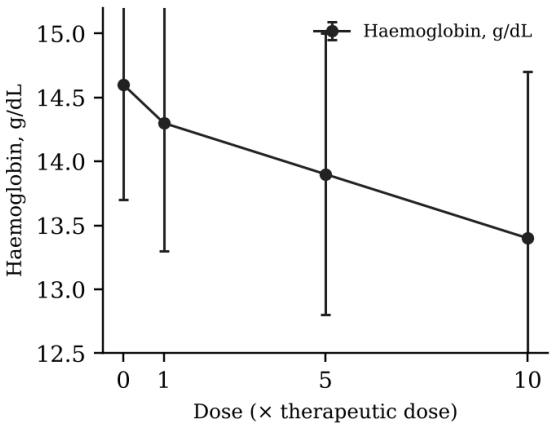

Figure 1. Haemoglobin on day 29 by dose group (mean ± SD).

tween groups (Table 2). Small increases in ALT, creatinine and urea at the higher doses were within normal limits and were not considered toxicologically significant.

Table 2. Biochemical values on day 29 (mean ± SD).

Parameter	Control	1 × TD	5 × TD	10 × TD
ALT, U/L	42 ± 8	44 ± 9	47 ± 10	51 ± 12
Creatinine, mg/dL	0.52 ± 0.07	0.53 ± 0.08	0.57 ± 0.09	0.60 ± 0.11
Urea, mg/dL	34 ± 5	35 ± 6	37 ± 6	39 ± 7
Glucose, mg/dL	96 ± 11	94 ± 12	92 ± 10	90 ± 12

All differences from control not significant (P > 0.05).

Histopathology showed mild tubular epithelial degeneration in the kidneys of one rat at 5 × TD and three at 10 × TD, and intranuclear inclusion bodies in two rats at 10 × TD (Table 3). These findings were mild, focal and within the range of spontaneous lesions reported in this strain, and were considered incidental. No abnormalities were seen in the brain, heart, spleen or lungs.

Table 3. Histopathological findings.

Finding	Control	1 × TD	5 × TD	10 × TD
Kidney: mild tubular epithelial degeneration	0/10	0/10	1/10	3/10
Kidney: intranuclear inclusion bodies	0/10	0/10	0/10	2/10
Liver: focal fatty change	1/10	1/10	1/10	2/10
Brain, heart, spleen, lung	Normal	Normal	Normal	Normal

Findings were considered incidental or within the range of background lesions in this strain.

4 Discussion

This study, conducted according to OECD Test Guideline 407 [4], shows that classically prepared Naga bhasma produces no significant toxicity in rats at up to ten times the human therapeutic dose over 28 days. The NOAEL was therefore 10 × TD, providing a tenfold margin of safety. These findings agree with the review by Nagarajan and colleagues [2] and with the repeated-dose study of Trivanga bhasma [3], and they confirm that the classical processing of lead converts it into a non-toxic form.

Concerns about lead in Ayurvedic medicines have been driven largely by studies of products bought over the internet. One such study estimated lead bioaccessibility in simulated gastric and intestinal fluids [5]. However, laboratory extraction tests do not reflect the complex physiology of the living gut, and our in vivo study provides a more realistic assessment. The absence of significant changes in haemoglobin, kidney function and the brain demonstrates that the lead in Naga bhasma is not absorbed in toxicologically relevant amounts.

The changes in kidney histology are worth comment. Mild tubular changes are common in rats and are influenced by age, diet and strain. Because they occurred in only a minority of animals and were not accompanied by significant changes in creatinine or urea, we consider them incidental.

Our results support the continued use of Naga bhasma at classical doses. Because the margin of safety is wide, Naga bhasma can be used for long-term treatment of chronic conditions such as diabetes and skin diseases, and there is no reason to restrict its use in children or pregnant women when prescribed by a qualified physician.

5 Conclusion

Classically prepared Naga bhasma is non-toxic in rats at up to ten times the therapeutic dose. It is safe for long-term human use at classical doses.

Competing interests. The teaching pharmacy of the first author's institution manufactures Naga bhasma.

References

[1] Dash MK, Joshi N, Dwivedi L, Dubey VS, Dwivedi KN. Characterization of lead sulfide obtained from Naga Bhasma. *J Ayurveda Integr Med.* 2024;15(2):100864. doi:10.1016/j.jaim.2023.100864

[2] Nagarajan S, Sivaji K, Krishnaswamy S, Pemiah B, Rajan KS, Krishnan UM, et al. Safety and toxicity issues associated with lead-based traditional herbo-metallic preparations. *J Ethnopharmacol.* 2014;151(1):1–11. doi:10.1016/j.jep.2013.10.037

[3] Jamadagni PS, Jamadagni SB, Singh R, Gaidhani SN, Upadhyay S, Hazra J. Repeated dose oral toxicity of Trivanga Bhasma in Swiss albino mice. *Ayu.* 2013;34(1):118–123. doi:10.4103/0974-8520.115449

[4] Organisation for Economic Co-operation and Development. Test No. 407: Repeated dose 28-day oral toxicity study in rodents. OECD Guidelines for the Testing of Chemicals, Section 4. Paris:

OECD Publishing; 2008.

[5] Koch I, Moriarty M, House K, Sui J, Cullen WR, Saper RB, et al. Bioaccessibility of lead and arsenic in traditional Indian medicines. *Sci Total Environ.* 2011;409(21):4545–4552. doi:10.1016/j.scitotenv.2011.07.059